

PATIENT

Malikai Kelly

SPECIES

Canine

BREED

Belgian Malinois

SEX

Female Spayed

AGE

2.8 years

WEIGHT

60.7lbs

PRESENTING CLINICAL SIGNS

History: Malikai is referred to evaluate a heart murmur. She is doing well - good appetite. Very active. On exam: NSR, no murmurs noted, PSS, lung fields clear, mm pink, moist, CRT<2. Blood pressure not taken prior to sedation. Sedated BP: 110mmHg. No medications *Sedated with propofol for study.

ECHOCARDIOGRAM FINDINGS

2D, m-mode, color flow and Doppler imaging is available.

Left ventricle: The LV diameter is normal with adequate myocardial function. LV wall thicknesses are normal.

Left atrium: The left atrium is normal.

Mitral valve: The mitral valve is mildly thickened with no prolapse into the left atrial lumen. Trivial mitral regurgitation.

Aortic valve/Aorta: The aortic valve is normal in morphology and mobility. Normal aortic outflow velocity; laminar flow. No aortic insufficiency.

Right ventricle: Normal right ventricular diameter and morphology indicating no overt evidence of pulmonary arterial hypertension.

Right atrium: Normal RA dimension.

Tricuspid valve: The tricuspid valve appears normal with no tricuspid regurgitation.

Pulmonic valve/Pulmonary artery: The pulmonic valve is normal in morphology and mobility. No pulmonic insufficiency. Normal RVOT velocity; laminar flow.

Pericardium/other: No pericardial or pleural effusion noted. No obvious cardiac masses.

Heart rhythm: ECG reveals a sinus rhythm with an average HR of 100 bpm.

INTERPRETED BY

Maggie Machen
Lamy, DVM
DACVIM (Cardiology)

2-Dimensional Measurements

| | |
|--------------------|-----|
| Ao diam (cm) | 2.1 |
| LA diam (cm) | 2.7 |
| LA:Ao (Swe) | 1.3 |
| IVS thickness (cm) | 1.1 |
| LVID diastole (cm) | 3.6 |
| PW thickness (cm) | 1.1 |
| LVID systole (cm) | 2.5 |
| FS (%) | 30 |

Doppler Measurements

| | |
|----------------|------|
| PV Vmax (m/s) | 0.88 |
| AoV Vmax (m/s) | 1.6 |
| MR Vmax (m/s) | NA |
| TR Vmax (m/s) | NA |
| TR PG (mmHg) | NA |

IMAGING

PERFORMED BY

Pamela Harrigan,
RDCS

INTERPRETATION OF THE FINDINGS

Overtly normal cardiac structure and function. No cause of the murmur is identified in this study. Trivial MR is noted; however, this is unlikely to be heard on physical exam. In the absence of significant volume changes (dehydration) or anemia, other possibilities include a physiologic flow murmur only present with elevated heart rates, or a small flow abnormality not seen here. Baseline lab work is recommended if not recently performed.

It is reasonable to monitor periodically via recheck echocardiography in the future, particularly should the murmur persist/progress. No significant valvular insufficiencies were noted, and no structural issues identified.

HOSPITAL NAME

Mass Veterinary Services

REFERRING VET

Dr. Masloski

INVOICE

30447

DATE

4/26/23



PATIENT

Malikai Kelly

SPECIES

Canine

BREED

Belgian Malinois

SEX

Female Spayed

AGE

2.8 years

WEIGHT

60.7lbs

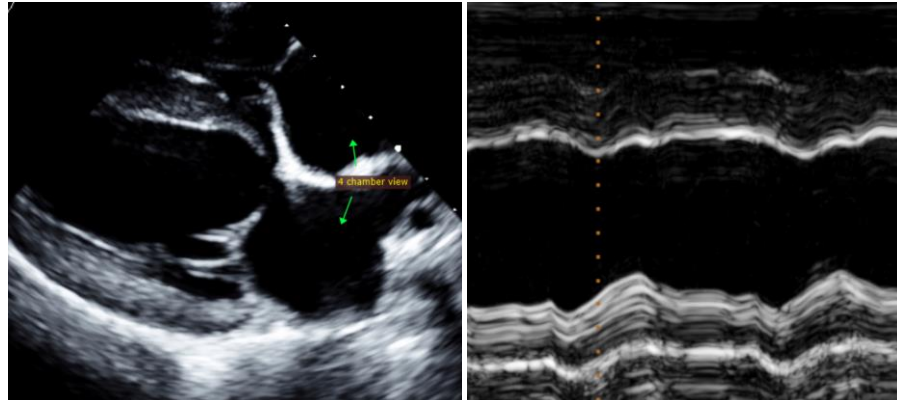
RECOMMENDATIONS

- No cardiac medications are indicated at this time. Monitor for any development of cough, labored breathing or exercise intolerance.
- No cardiac contraindication for general anesthesia.

PLAN

- Recommend recheck echocardiogram in 12-18 months to screen for progression or development of concurrent cardiac disease that the preexisting murmur may mask.

IMAGES



INTERPRETED BY

Maggie Machen Lamy, DVM
DACVIM (Cardiology)

The information and recommendations provided are based on the images presented by the referring veterinarian. No evaluation can be communicated regarding pathology that was not visible in the image/video clips provided.

Thank you for this referral. This report was generated using transcription software, and minor dictation errors may be present. If the clinical or image interpretation does not parallel your findings or if I can be of any further assistance, please contact me.

IMAGING PERFORMED BY

Pamela Harrigan, RDCS

Maggie Machen Lamy, DVM
Diplomate of the American College of Veterinary Internal Medicine (Cardiology)
info@sonopath.com

HOSPITAL NAME

Mass Veterinary Services

Echocardiogram performed by: Pamela Harrigan, RDCS
Pet Animal Ultrasound Service (4paus.com)

REFERRING VET

Dr. Masloski

INVOICE

30447

DATE

4/26/23